

Original article:

An update in MRI of cholesteatoma.

***Dr.Rajshree Gupta , **Dr.Beni Prasad**

*Resident, ** Head of Department

Department of ENT, National institute of medical science & research, Jaipur (Rajasthan)

Corresponding author**

Abstract.

An update in Magnetic resonance imaging of cholesteatoma. Objective: To report on the value and limitations of new MRI techniques in pre- and post-operative MRI of cholesteatoma. The current value of magnetic resonance imaging (MRI) in diagnosing congenital, acquired, and post-operative recurrent or residual cholesteatoma is described.

Methodology and results: High resolution computed tomography (HRCT) is still considered the imaging modality of choice for detecting acquired or congenital middle ear cholesteatoma. However, MRI may provide additional information on the delineation and extension of cholesteatoma and on potential complications. Detecting post-operative residual or recurrent cholesteatoma with HRCT was shown to be inaccurate due to the technique's low sensitivity and specificity.

Conclusions: Recently, improvements in MRI techniques have led to a more accurate diagnosis of cholesteatoma using delayed contrast enhanced T1-weighted imaging and diffusion-weighted imaging.

Key-words.Cholesteatoma; middle ear; diffusion-weighted MRI; computed tomography

Introduction

Confirming a diagnosis of acquired or congenital cholesteatoma through imaging techniques remains a challenge for the head and neck radiologist. The diagnosis of an acquired cholesteatoma is mostly based on clinical suspicion (otoscopic findings, conductive or mixed hearing loss, and/or otorrhea). High resolution computed tomography (HRCT) is still widely considered to be the primary imaging tool for diagnosing and documenting the extent and potential complications of middle ear cholesteatoma. HRCT provides good information on the presence of associated bony and ossicular erosion as well as on important pre-operative anatomical features, such as the delineation of the tympanic segment of the facial nerve, the tegmen, the position of the sigmoid sinus, and the size of the mastoid cell structure.¹

The additional value of MRI in primary acquired cholesteatoma is due mainly to its capacity to unequivocally confirm the diagnosis of cholesteatoma in cases of clinical doubt; in its capacity to distinguish cholesteatoma from other soft tissues, such as fibrosis, granulation tissue and cholesterol granuloma; and its potential to document invasion of the labyrinth and of the intracranial space.¹⁻³ In contrast, many studies have shown that HRCT is inaccurate in detecting post-operative residual and recurrent cholesteatoma.^{4,5} In completely aerated postoperative cavities absent of any associated soft tissue, HRCT has a high negative predictive value in excluding cholesteatoma. However, HRCT is unable to differentiate cholesteatoma from scar tissue, granulation tissue, or cholesterol granuloma in completely or partially opacified middle ears and post-operative cavities.^{4,5} MRI offers the possibility of using

different types of sequences — including diffusion weighted sequences and late post-gadolinium T1-weighted images — and different imaging planes.² In the past few years, MRI, including diffusion-weighted (DW) echo-planar imaging (EPI), has become increasingly important in the detection and further characterization of cholesteatoma.⁶⁻⁹ MRI can differentiate granulation tissue from cholesteatomatous tissue, but often fails to clearly detect residual or recurrent cholesteatoma in the ears postoperatively.^{3,10} Therefore, non-echo-planar DW imaging (DWI) techniques have been tested to see if they could overcome these limitations.

MRI characteristics of cholesteatoma

Cholesteatoma is a cystic lesion formed from keratinized, stratified, squamous epithelium (matrix) filled with desquamation debris (keratin), which commonly involves extradural structures. Predominantly, these structures include the middle ear cavity and mastoid, but also involve other parts of the petrous bone, including the petrous apex and the external auditory canal. Extradural cholesteatoma has traditionally been divided into either congenital or acquired cholesteatoma. Intradurally-located lesions are often found in the cerebellopontine angle or middle cranial fossa, and are known as epidermoid cysts.

On standard T1-weighted MRI sequences, a cholesteatoma, both congenital and acquired ones, have a hypointense signal intensity when compared with the brain's gray matter. A cholesteatoma is a non-vascularised lesion; therefore, it is not enhanced after intravenous gadolinium administration. Theoretically, the enhancement of the surrounding epithelial (matrix) and granular (perimatrix) layers can be seen as a thin, enhanced line (peripheral rim) on

T1-weighted images after intravenous administration of gadolinium; but this is often not discernible because of associated inflammation, which enhances the image surrounding the lesion. On T2-weighted images, cholesteatoma is characterized by an intermediate to high signal intensity, which is definitely lower than the intensity of inflammatory tissue or fluid. Inflammation or fibrous tissue, on the contrary, is characterized by a high signal intensity on T2-weighted images and a low signal intensity on T1-weighted images, although these are variably and inhomogeneously enhanced after intravenous administration of gadolinium. It often takes 45 minutes for fibrous tissue to show enhancement, which warrants late imaging after gadolinium administration. A cholesterol granuloma on a MRI characterized by high signal intensities on both T1- and T2-weighted images. On diffusion-weighted MRI sequences (echo-planar as well as non-echo-planar), a cholesteatoma is characterized by a clear hyperintensity. The DW-MRI was initially used to diagnose ischemic brain infarction.¹¹ The DW-MRI technique provides information about the diffusion motion of water (protons) and the restriction of this motion within various biologic tissues and pathological entities. In order to visualize the diffusion of water (protons), diffusion-sensitizing gradients must be applied, most often using a fast, single-shot gradient echo sequence (b-values of 1000s/mm²).^{1,6,9}

The precise cause of the increased signal intensity of cholesteatoma on DW-MRI is still unknown. Several authors believe that the hyperintensity is caused by a combination of restricted diffusion and the T2 shine-through effect.^{6,7,9} The cholesteatoma, which is filled with cholesterol containing keratin debris, has a

moderate to high signal intensity on standard T2-weighted MRIs, suggesting that the T2 shine through effect may contribute to the hyperintensity on diffusion weighted images. No false-positive findings were seen in our population. Recently, several authors reported low-intermediate intensities in the presence of silastic, bone powder, and granulation tissue.¹²⁻¹⁴ However, a marked hyperintensity on DWI is considered diagnostic for cholesteatoma, but one must be careful not to misinterpret the numerous artefacts on DWIs as cholesteatomas. The differential diagnosis and imaging characteristics of cholesteatoma on MRI are summarized in Table 1, and 3 case illustrations are described in Figures 1, 2, and 3.

Detection of primary, recurrent, and residual cholesteatoma

Two types of MRI protocols were recently described for the preoperative detection and differentiation of middle ear cholesteatoma and post-operative detection of residual and recurrent cholesteatoma. These include the delayed post-gadolinium MRI,⁵⁻¹⁶ and the diffusion-weighted

imaging techniques, including echo-planar (EPDWI)^{6-9,13,14} and non-echo-planar (non-EP-DWI) sequences.^{12,17-20}

Delayed post-gadolinium magnetic resonance imaging With early scanning, slowenhancing inflammatory and scar tissue can be mistaken for cholesteatoma, causing false positive results. Williams and Ayache described the use of late post-gadolinium T1-weighted sequences in the detection of post-operative residual cholesteatoma.^{15,16} They performed a T1-weighted sequence 45 minutes after intravenous gadolinium administration, differentiating non-enhancing and avascular cholesteatoma from slow enhancing inflammatory and/or scar tissue. Using this protocol, they were able to detect postoperative residual cholesteatoma pearls as small as 3 mm.^{14,15} However, the administration of intravenous gadolinium is expensive, and has become controversial since the appearance of systemic nephrogenic sclerosis in patients with renal insufficiency.²¹

Table 1:
Differential diagnosis and imaging characteristics of cholesteatoma on MRI

	T2-weighted MRI	T1-weighted MRI	T1-weighted MRI with gadolinium	Diffusion-weighted MRI
Cholesteatoma	Hyper-intensity	Hypo-intensity	Hypo-intensity Peripheral rim (matrix)	Hyper-intensity
Cholesterol granuloma	Hyper-intensity	Hyper-intensity	Hyper-intensity	Low intermediate
Inflammation/scar tissue	Hyper-intensity	Hypo-intensity	Hyper-intensity	No signal

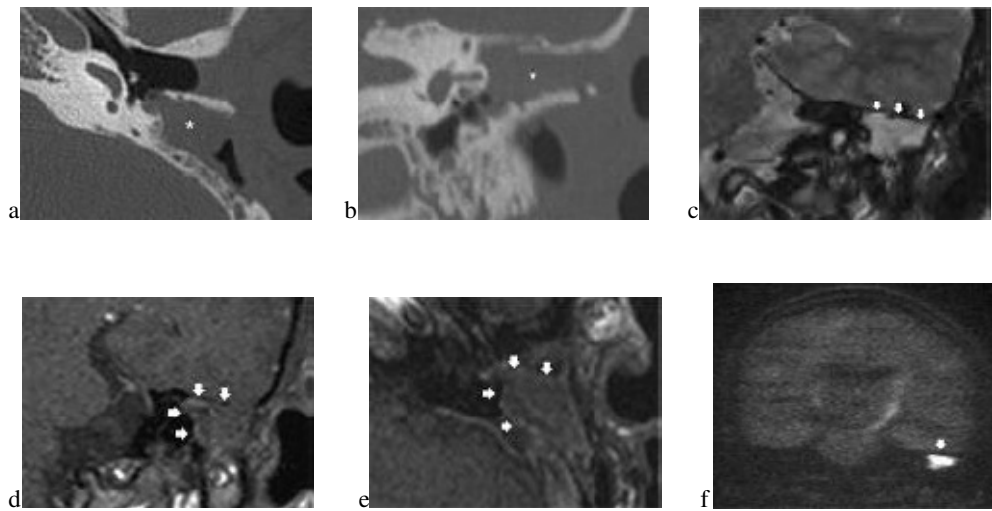


Figure 1

A 23-year-old man with a prior history of cholesteatoma surgery on the left side (> 3 years), with a micro-otoscopic suspicion of a recurrent cholesteatoma. Surgery showed the presence of a large recurrent cholesteatoma involving the attic and mastoid;

a: Axial HRCT image at the level of the basal turn of the cochlea on the left side. The entire post-operative mastoid cavity is almost completely filled with soft tissue (asterisk). On HRCT, it is impossible to differentiate these soft tissues; a recurrent cholesteatoma is likely, although it can neither be excluded nor confirmed by HRCT; **b:** Coronal-reformatted CT image at the level of the vestibule. Again, the entire cavity is filled with soft tissue (asterisk) which cannot be differentiated on CT. Based on this CT examination, a recurrent cholesteatoma can neither be excluded nor confirmed; **c:** Coronal T2-weighted image (at the same level as Figure 1b) through the left temporal bone showing a cavity almost completely filled with a hyper-intense nodular lesion (arrows); **d:** Coronal late (45 minutes) post-gadolinium T1-

weighted MRI (at the same level as Figures 1b and 1c). The cholesteatoma is seen as a large hypointense nodular lesion (arrows) surrounded by inflammatory and scar tissue that enhance the image. A large cholesteatoma presenting as a characteristic, non-enhancing, hypo intense lesion; **e:** Axial late (45 minutes) post-gadolinium T1-weighted MRI at the level of the vestibule. Note the large, hypo-intense, non-enhancing nodular lesion in the cavity (arrows) delineated by peripherally enhanced inflammatory and / or scar tissue; diagnosis of a large cholesteatoma presenting as a characteristic non enhancing, hypo-intense lesion; **f:** Coronal single-shot turbo spin-echo diffusion-weighted sequence (SS TSE DWI; a non-EPI-based diffusion-weighted image) at the level of the left temporal bone. The cholesteatoma is clearly seen (arrow) as a very hyper-intense lesion under the left temporal lobe. The presence of hyper-intensity is pathognomonic for a large recurrent cholesteatoma in the mastoid cavity. Note that there is no extension of the cholesteatoma into the middle fossa.

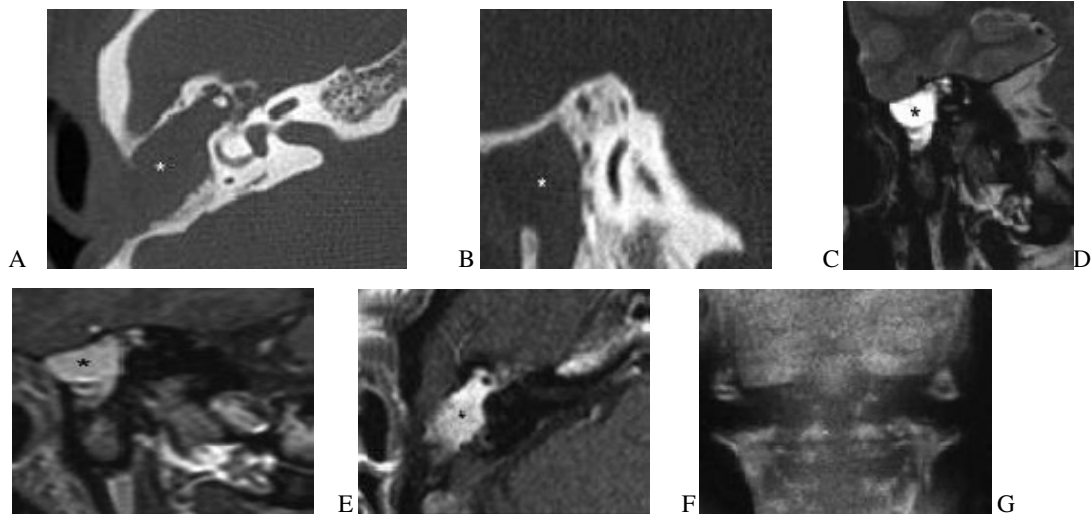


Figure 2

A 52-year-old woman evaluated 18 months after surgery for a primary cholesteatoma on the right side, prior to possible second-look surgery. Based on this investigation, no second look surgery was performed. Clinical micro-otoscopic follow-up 26 months after the primary surgery showed no suspicious signs of residual or recurrent disease. **a:** Axial HRCT image at the level of the lateral semi - circular canal on the right side. The entire post-operative mastoid cavity is almost completely filled with soft tissue (asterisk). On HRCT, it is impossible to differentiate these soft tissues; a recurrent or residual cholesteatoma can neither be excluded nor confirmed by HRCT; **b:** Coronal reformatted CT image at the level of the lateral semicircular canal on the right side. Again, the entire cavity is filled with soft tissue (asterisk) which cannot be differentiated on CT. Based on this CT examination, a cholesteatoma can neither be excluded nor confirmed; **c:** Coronal T2-weighted image (at the same level as Figure 2b) through the right temporal bone showing a mastoid cavity almost completely filled with a high-intensity lesion (asterisk); **d:** Coronal late (45 minutes)

post-gadolinium T1-weighted MRI (at the same level as Figures 2b and 2c). The mastoid cavity is filled with a lesion that is completely enhancing, suggesting the presence of inflammatory and scar tissue (asterisk) without the presence of a recurrent of residual cholesteatoma; **e:** Axial late (45 minutes) post-gadolinium T1-weighted MRI at the level of the lateral semicircular canal. The mastoid cavity is filled with a lesion that is completely enhancing, suggesting the presence of inflammatory and scar tissue (asterisk) without the presence of recurrent of residual cholesteatoma; **f:** Coronal single-shot turbo spin-echo diffusion-weighted sequence (SS TSE DWI; a non-EPI based diffusion weighted image) at the level of the right temporal bone. No clear nodular hyper-intense lesions can be seen excluding the presence of cholesteatoma (compare with the signal intensity of Figures 1f and 3e).

Diffusion-weighted imaging (DWI): echo-planar versus non-echo planar DWI

The use of EP-DWI in the differentiation of middle ear cholesteatoma from inflammatory changes was originally described by Fitzek

al.,⁶who identified middle ear cholesteatoma as hyperintense lesions (white) in the hypo-intense signal void (black) of bone, and air in the temporal bone and middle ear. The major disadvantage of EP-DWI is the presence of important susceptibility artefacts at the air-bone interface at the base of the skull, the variable distortion of the images, and the low spatial resolution. Several reports highlight the value of EP-DWI in the preoperative evaluation of middle ear cholesteatoma,⁹ and in the postoperative

follow-up of residual or recurrent cholesteatoma.⁷⁻⁹ EP-DWI seems to be very reliable in detecting primary acquired middle ear and large recurrent cholesteatomas.⁹ Several reports set the detection threshold of EP-DWI for cholesteatoma at 5 mm.⁷⁻⁹ This 5-mm size limitation is the main reason why EP-DWI cannot be used to detect small residual cholesteatoma pearls before a second look surgery.⁹

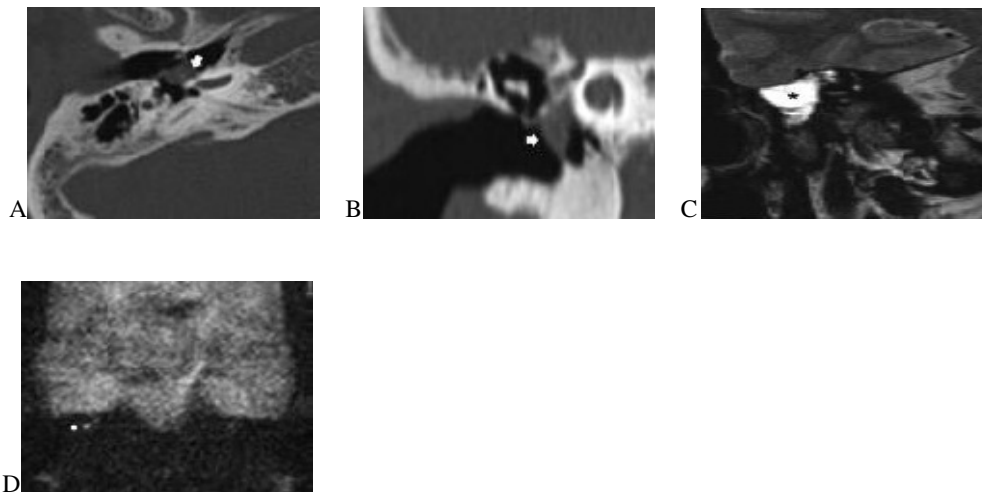


Figure 3

A 55-year-old woman was referred to our department with a prior history of an endauraltympanoplasty (< 13 months ago) on the right side, presenting with chronic ear discharge and conductive hearing loss. Micro-otoscopy suggested a small residual cholesteatoma behind the tympanic membrane. Surgery revealed a 3-4 mm, small residual cholesteatoma. **a:** Axial HRCT image at the level of the basal turn of the cochlea on the right side shows a small mesotympanic nodular mass (arrow) behind an intact tympanic membrane. On HRCT, a residual cholesteatoma is probable, but can neither be

excluded nor confirmed; **b:** Coronal reformatted CT image at the level of the right cochlea. Again, in the middle ear cavity, a small nodular mass (arrow) is detected behind an intact tympanic membrane. Based on this CT examination, a residual cholesteatoma, although likely, can neither be excluded nor confirmed; **c:** Coronal late (45 minutes) post-gadolinium T1-weighted MRI (at the same level as Figure 3b). The cholesteatoma is seen as a small hypo-intense nodular lesion (arrow) surrounded by a small layer of enhanced inflammatory and scar tissue; **d:** Coronal single-shot turbo spin-echo diffusion-

weighted sequence (SS TSE DWI; a non-EPI based diffusion weighted image) at the level of the right temporal bone. The cholesteatoma is clearly seen (arrow) as a hyper-intense lesion under the right temporal lobe. The presence of hyper-intensity is pathognomonic for a small residual cholesteatoma

A non-echo-planar based diffusion-weighted sequence (non- EP-DWI) has recently been described for the evaluation of middle ear cholesteatoma.¹⁷ This sequence uses a single shot turbo spin echo diffusion weighted sequence (SS TSE DWI) with a 180° radio-frequency refocusing pulse for each measured echo, which reduces the susceptibility for artefacts. Compared with the EP-DWI, this sequence has a higher resolution and thinner slice thickness (2 mm) and can show cholesteatoma as small as 2 mm prior to primary^{18,19} and second look surgery.^{19,20} A prospective evaluation of this non-EP DWI sequence revealed a high sensitivity for the detection of congenital or acquired middle ear cholesteatoma.¹⁸ Of 21 surgically- confirmed cholesteatomas,¹⁹ were diagnosed with non- EP-DW images. One false negative case was missed due to spontaneous auto-evacuation of a retraction cholesteatoma (absence of keratin responsible for the hyper-intensity). Small retraction pockets or evacuated cholesteatoma with an absence of keratin accumulation can be missed on DWI, as previously reported.^{7,9} Theoretically, apart from this auto-evacuation, a cholesteatoma can also evacuate as a result of suction cleaning of the affected ear by the ENT. The other false-negative case in a child with a 3-mm congenital cholesteatoma was caused by a degraded image quality caused by motion artifacts. A recent investigation by De Foeret al.²⁰ indicated that non EP-DWI sequences have

the highest sensitivity for evaluating patients prior to second-look surgery. In our ENT department, non-EP DWI effectively replaces second-stage surgery, thus avoiding unnecessary interventions. The follow-up MRI after primary cholesteatoma surgery is performed routinely after 1 and 5 years. An overview of recent reports, which highlight the value of MRI principals in detecting recurrent and/or residual cholesteatoma, is given in Table 2.

MRI protocol

Our current MRI protocol for the pre-operative evaluation of primary acquired and congenital cholesteatoma and for the postoperative follow-up of residual and/or recurrent cholesteatoma consists of a combination of both techniques, and is mostly based on late post-gadolinium T1-weighted images and non-EP DWI sequences using a 1.5 T superconductive unit (MagnetomAvanto, Siemens Medical Solutions, Erlangen, Germany) with the standard Head Matrix coil. We no longer perform any unenhanced T1- weighted images. All sequences are performed 45 minutes after administration of intravenous gadolinium. Axial 2-mm thick spin-echo T1-weighted images (TR 400 ms, TE 17 ms, matrix 192 ×256, field of view 150 mm ×200 mm) and coronal 2-mm thick spin-echo T1-weighted images are acquired with the same parameters, except for the matrix, which is set at 144 × 256 for the coronal images. Coronal 2 mm thick turbo spin-echo T2-weighted images (TR 3500 ms, TE 92 ms, matrix 192 ×256, field of view 150 mm ×200 mm) and axial 0.4 mm thick 3D turbo spin echo T2-weighted images (TR 1500 ms, TE 303 ms, matrix 228 ×448, field of view 107 mm ×210 mm) are also performed. In all patients, a 2-mm thick single-shot turbo spin-

echo diffusion-weighted sequence is acquired in the coronal plane (TR 2000 ms, TE 115 ms, matrix

134 ×192, field of view 220 mm ×220 mm, b factors 0, and 1000 mm²/sec). The coronal plane is preferred over the axial plane because in the past, using EP DWI, the coronal plane showed fewer artefacts. Out of

habit, the coronal plane is still preferred. This sequence takes less than 10 minutes and no gadolinium is used.

Surgical implications

The procedure of choice for the surgical treatment of middle ear cholesteatoma in our department

is the closed technique, or canal wall up (CWU) approach, with bony obliteration of the paratympanic

space (mastoid and antro-attic cells).^{22,23} This approach dramatically lowers the incidence of recurrent cholesteatoma to a level less than 2%, as observed during long-term otoscopic and imaging follow-up. To prevent late complications with obliteration techniques, follow-up safety measures are necessary to exclude

residualcholesteatoma. Traditionally, this implies second-stage surgery after one year. The definite improvement in the resolution and reliability of the non-EP DWI MRI technique encouraged us to use it for both pre-operative evaluations and post-operative follow -ups. In the pre-operative stage, the combined use of CT and MRI allows unambiguous confirmation of the diagnosis, the ability to show the extent of the

cholesteatoma, evaluate the risk for peri-operative sensory hearingloss related to labyrinthine fistulas,

to plan the surgical approach accordingly, and to counsel the patient. During the post-operative stage, the non-EP DWI MRI one and five years after the primary surgical event excludes the presence of residual cholesteatoma in a non-invasive way, thus avoiding unnecessary second-stage surgery in the majority of cases. The high sensitivity and specificity of the non-EP DWI sequence makes it possible to screen for residual cholesteatoma using this technique alone, even in a pediatric population.^{20A} A reliable interpretation of MRIs requires a high level of training and experience for both the otologic surgeon and radiologist before routinely using it to replace second-look surgery. While offering excellent longterm safety to the patient, this

protocol has considerably reduced the number of second-stage procedures.

Before the application of this new protocol, we performed routine second-stage surgery in 62% of the cholesteatoma cases.

Currently, with the application of this new protocol, we perform routine second-stage surgery in less than 10% of cases. As the overall medical cost of second-stage surgery is easily a factor of 10 times higher than the cost of MRI, the economic implications are obvious. There is also a marked reduction in emotional stress and loss of time for the patient. Another important issue and concern in the imaging follow- up of cholesteatoma patients is the exposure to radiation, implied by the still routinely used repeated CT follow-up. We state that MRI, including non-EP DWI and late post-gadolinium T1- weighted images, should be used rather than CT to evaluate patients before second-look surgery.

Conclusions

HRCT remains the most widely used imaging tool for diagnosing primary cholesteatoma. However, the role of MRI is quickly becoming more important in both the pre-operative assessment of primary acquired and congenital cholesteatoma, and in the postoperative follow-up screening for residual disease. In our

department, MRI has now replaced HRCT as the primary tool for pre-operatively diagnosing and characterizing cholesteatoma and for the post-operative follow-up screening for residual cholesteatoma. The value of HRCT for the pre-operative documentation of the cases remains high, providing the surgeon a surgical road map, which improves surgical planning and safety.

References

1. Lemmerling M, De Foer B. Imaging of cholesteatomatous and non-cholesteatomatous middle ear disease. In: Lemmerling M, Kollias S, eds. *Radiology of the petrous bone*. Springer, Berlin, 2004;31-47.
2. De Foer B, Vercruyse JP, Offeciers E, Casselman E. MR of cholesteatoma. In: Keir J, Moffat D, Sudhoff H, eds. *Recent advantages in Otolaryngology*. The Royal society of Medicine Press, London, 2008;1-23.
3. Martin N, Sterkers O, Nahum H. Chronic inflammatory disease of the middle ear cavities: Gd-DTPAenhanced MR imaging. *Radiology*. 1990;176:399-405.
4. Tierney PA, Pracy P, Blaney SP, Bowdler DA. An assessment of the value of the preoperative computed tomography scans prior to oto-endoscopic 'second look' in intact canal wall mastoid surgery. *ClinOtolaryngol Allied Sci*. 1999;24:274-276.
5. Blaney SP, Tierney P, Oyarazabal M, Bowdler DA. CT scanning in "second look" combined approach tympanoplasty. *Rev LaryngolOtolRhinol(Bord)*. 2000;121:79-81.
6. Fitzek C, Mewes T, Fitzek S, Mentzel HJ, Hunsche S, Stoeter P. Diffusion-weighted MRI of cholesteatomas in petrous bone. *J MagnReson Imaging*. 2002;15:636-641.
7. Aikele P, Kittner T, Offergeld C, Kaftan H, Hüttenbrink KB, Laniado M. Diffusion-weighted MR imaging of cholesteatoma in pediatric and adult patients who have undergone middle ear surgery. *AJR Am JRoentgenol*. 2003;181:261-265.
8. Stasolla A, Magliulo G, Parrotto D, Luppi G, Marini M. Detection of postoperative relapsing/residual cholesteatomas with diffusionweighted echo-planar magnetic resonance imaging. *OtolNeurotol*. 2004;25:879-884.
9. Vercruyse JP, De Foer B, Pouillon M, Somers T, Casselman J, Offeciers E. The value of diffusion-weighted MR imaging in the diagnosis of primary acquired and residual cholesteatoma: a surgical verified study of 100 patients. *EurRadiol*. 2006;16:1461-1467.
10. VandenAbeeel D, Coen E, Parizel PM, Van de Heyning P. Can MRI replace a second look operation in cholesteatoma surgery? *ActaOtolaryngol*. 1999;119:555-561.
11. Huisman TA. Diffusion-weighted imaging: basic concepts and application in cerebral stroke and head trauma. *EurRadiol*. 2003;13:2283-2297.

12. Dubrulle F, Souillard R, Chechin D, Vaneecloo M, Desaulty A, Vincent C. Diffusion-weighted MR imaging sequence in the detection of post - operative recurrent cholesteatoma. *Radiology*.2006;238:604-610.
13. Jeunen G, Desloovere C, Hermans R, Vandecaveye V. The value of magnetic resonance imaging in the diagnosis of residual or recurrent acquired cholesteatoma after canal wall-up tympanoplasty. *OtolNeurotol*. 2008; 28:16-18.
14. Venail F, Bonafe A, Poirrier V, Mondain M, Uziel A. Comparison of echo-planar diffusion-weighted imaging and delayed postcontrast T1-weighted MR imaging for the detection of residual cholesteatoma. *AJNR Am J Neuroradiol*. 2008;29: 1363-1368.
15. Williams MT, Ayache D, Alberti C, et al. Detection of postoperative residualcholesteatoma with delayed contrast enhanced MR imaging: initial findings. *EurRadiol*. 2003;13:169-174.
16. Ayache D, Williams MT, Lejeune D, Corré A. Usefulness of delayed postcontrast magnetic resonance imaging in the detection of residual cholesteatoma after canal wall-up tympanoplasty. *Laryngoscope*.2005; 115:607-610.
17. De Foer B, Vercruyse JP, Pilet B, et al. Single-shot, turbo spin-echo,diffusion-weighted imaging versus spin-echo-planar, diffusion-weightedimaging in the detection of acquiredmiddle ear cholesteatoma. *AJNR Am J Neuroradiol*. 2006;27:1480-1482.
18. De Foer B, Vercruyse JP, Bernaerts A, et al. The value of single- shot turbo spin-echo diffusion weighted MR imaging in the detection of middle ear cholesteatoma. *Neuroradiology*. 2007;49:841-848.
19. Vercruyse JP, De Foer B, Bernaerts A, et al. The value of single-shot turbo spin-echo diffusion weighted magnetic imaging in the diagnosis of congenital, acquired and residual cholesteatoma: A surgical verified study of 60 patients. *B-ENT*. 2007;3Suppl 5:17.
20. De Foer B, Vercruyse JP, Bernaerts A, et al. Detection of postoperative residual cholesteatoma with non-echo-planar diffusion-weighted magnetic resonance imaging. *OtolNeurotol*. 2008;29:513-517.
21. Sadowski EA, Bennett LK, Chan MR, et al. Nephrogenic systemic fibrosis: risk factors and incidence estimation. *Radiology*. 2007;243:148-157.
22. Offeciers E, Vercruyse JP, De Foer B, Casselman J, Somers T. Mastoid and epitympanic obliteration. The bony obliteration technique. In: *Ars B, ed. Chronic Otitis Media. Pathogenesis-Oriented Therapeutic Management*.Kugler Publications, Amsterdam; 2008:299-327.
23. Vercruyse JP, De Foer B, Somers T, Casselman JW, Offeciers E. Mastoid and epitympanic bony obliteration in pediatriccholesteatoma. *OtolNeurotol*. 2008;29:953-960.